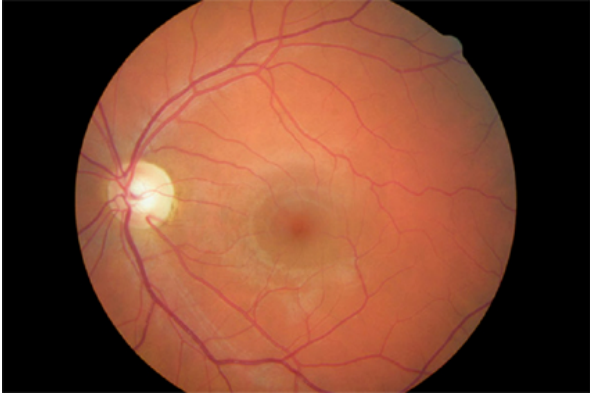
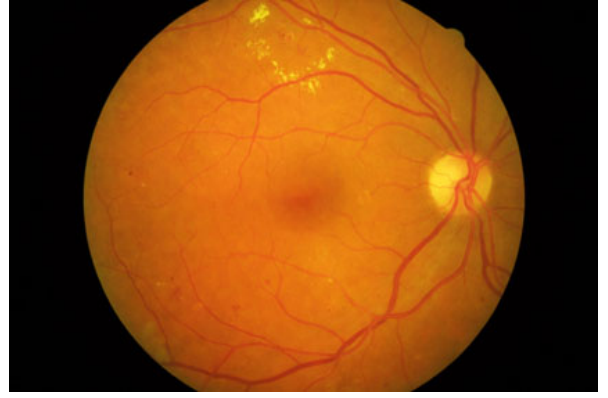
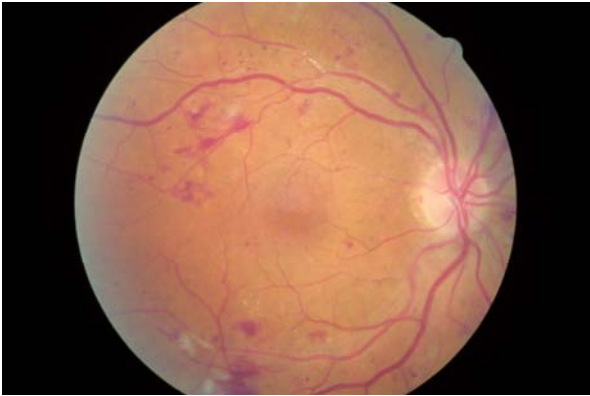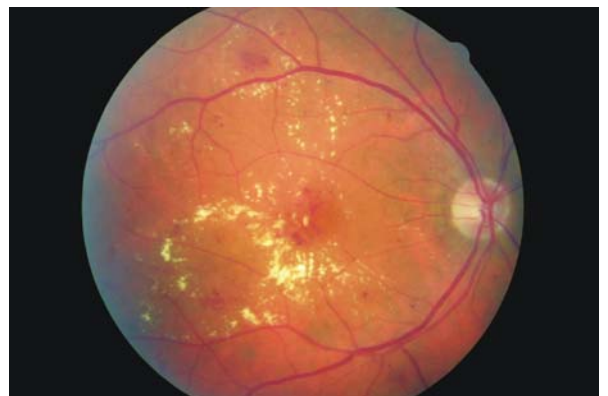
Normal retina with no diabetic retinopathy - NSC grade R0



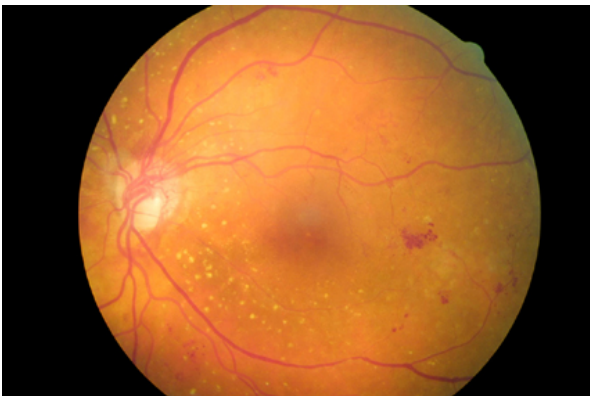
Background diabetic retinopathy with microaneurysms, haemorrhages and exudates - NSC grade R1



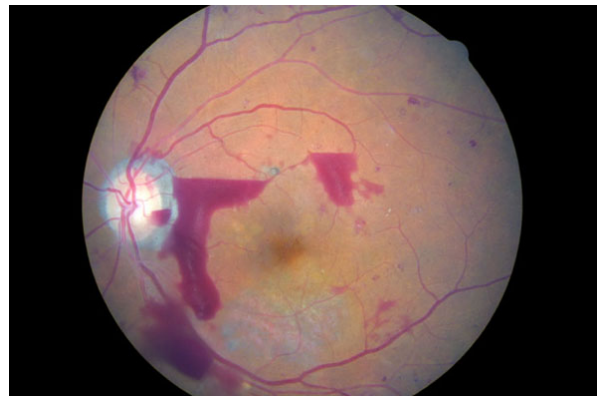
Pre-proliferative diabetic retinopathy with CWS, IRMA and multiple blot haemorrhages - NSC grade R2



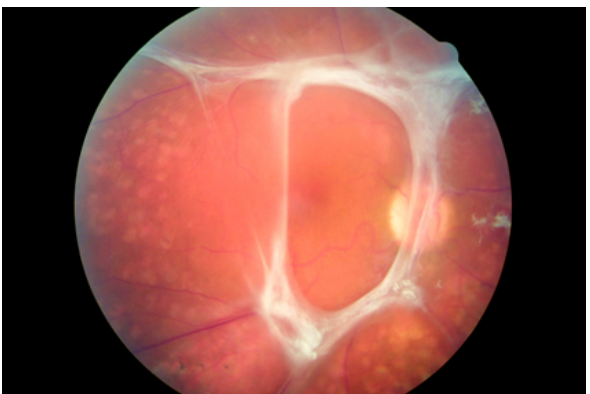
Diabetic maculopathy with haemorrhages and circinate exudates - NSC grade M



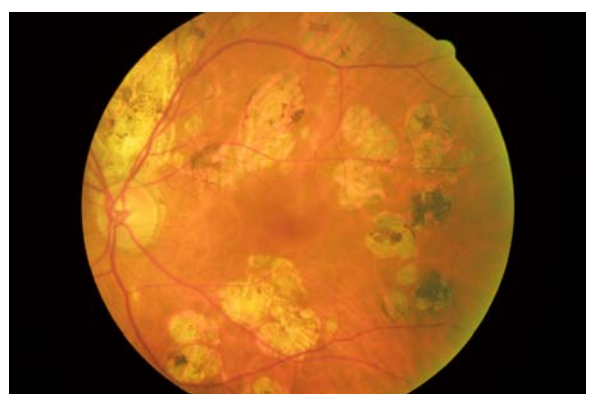
Proliferative diabetic retinopathy with new vessels at the optic disc (NVD) - NSC grade R3



Proliferative diabetic retinopathy with pre-retinal and vitreous haemorrhages - NSC grade R3



Proliferative diabetic retinopathy with fibrous proliferation - NSC grade R3



Evidence of previous laser therapy - NSC grade P